

PATIENT

Rose Berlinicke

SPECIES

Feline

BREED

Domestic Short Hair

SEX

Female Spayed

AGE

2005

WEIGHT

6.45lbs

INTERPRETED BY

Maggie Machen Lamy,
DVM, DACVIM
(Cardiology)

HOSPITAL NAME

Cat Hospital At Towson

REFERRING VET

Dr. Fitzgerald

INVOICE

20757

DATE

8/26/21

PRESENTING CLINICAL SIGNS

History: Patient presented in June 2021 for severe hepatopathy post methimazole treatment started for hyperthyroidism. Anorexia and jaundice noted at home. Supportive care until Radiocat appt done early August. Pre-radiocat chest radiographs attached. Patient greatly improved post treatment until abnormal episode 8/20 with late night dizziness (per owner) and ataxia progressing to acute loss of hind limb function for long period. Patient returned to normal by following morning. Follow up veterinary visit the next day showed stable examination with no murmur or arrhythmia on auscultation, a strong and synchronous pulse, normal neurologic examination and normal gait. No appreciable abnormalities.

-Pertinent abnormal PE/Chem/CBC/UA Results: ProBNP 756 pmol/L, ALT mildly elevated but improved from recent history.

-Current medications: Clopidogrel 75mg - 1/4 tab PO SID started 8/21/21

-Sedation used: No sedation necessary.

-STAT: Not requested.

ELECTROCARDIOGRAPHIC FINDINGS *Note: Single lead ECGs are evaluated as a rhythm strip. Morphology/MEA cannot be definitively commented on.

A single lead ECG is available; 50mm/s, 10mm/mV. The average heart rate is 200bpm with a largely regular rhythm. The rhythm is sinus in origin, with a p for every QRS complex and vice versa. The QRS is inverted. Two isolated premature beats are identified; APCs suspected although a 6 lead tracing would be ideal to confirm. No pauses or other dysrhythmias observed.

ECG diagnosis: Normal sinus tachycardia with isolated premature beats.

ECHOCARDIOGRAM FINDINGS

2D, m-mode, color flow and doppler imaging is available. The left ventricular wall is borderline normal in dimension. There is a diffusely hyperechoic endocardium consistent with fibrosis. The papillary muscles are mildly remodeled and hyperechoic. The left atrium is normal in size. The right atrium is normal in size. The right ventricle appears normal. The mitral valve is normal in structure and mobility. Blood flow through both the LVOT and RVOT is normal in velocity. No pleural or pericardial effusion seen. No obvious cardiac tumors.

CARDIAC CHART

FELINE CARDIAC PARAMETERS	BODY WEIGHT (kg)	HR (BPM)	IVSd (cm) (Moise, Pipers)	LVIDd (cm) (Moise, Pipers)	LVWd (cm) (Moise, Pipers)	FS (%)	EF (%)
NORMAL PARAMETER	-----	150-240	3.5-0.55	<2 (mean 1.5)	3.5-0.55	35-67	80-100
PATIENT	2.9	225	0.57	1.0	0.54	60	94
FELINE CARDIAC PARAMETERS	LA/AO (Boon)	LA/AO HEART BASE (Swe) (Abbott)	LA 2D short axis Base view (cm) (Abbott)		LVOT VEL (m/s)	RVOT VEL (m/s)	E max (m/s)
NORMAL	<1.5	<1.3	<1.2		<1.6	<1.3	<0.9
PATIENT	NM	1.3	1.2		0.9	1.2	NM

Adapted from June Boon, Veterinary Echocardiography, 1998
Abbott J & MacLean H JVIM 2006;20: 111-119, Moise et al. Am J Vet Res 47:1476, 1986. Pipers et al. Am J Vet Res 40:882, 1979.

INTERPRETATION OF THE FINDINGS & FURTHER RECOMMENDATIONS

Essentially normal cardiac structure and function. The LV wall thickness is borderline normal which may be a normal variant, may be indicative of early disease, or may simply be a secondary phenomenon with a history of hyperthyroidism. A baseline blood pressure is strongly recommended as a possible contributing factor to both echo changes and clinical issues. There is no evidence of elevated left atrial pressure. Serial echocardiography will be necessary to determine progression. No additional issues are identified.

Given these findings no medications are indicated. A normal left atrial size would make a cardiogenic thrombus highly unlikely. This does not rule out non-cardiac thrombi (typically due to neoplasia, hypercoagulability, etc) which should also be considered pending further evaluation. Further neurologic and orthopedic evaluation may also be useful. Again, a baseline BP is strongly recommended.

Isolated premature beats are identified on the included ECG. These are suspected to be atrial in origin given a similar appearance to the sinus complex; however, a 6 lead tracing would be ideal to fully evaluate. Regardless, these are largely benign and while they can develop with cardiac disease there is no evidence of significant structural disease on this exam. Extra-cardiac factors such as stress, pain, neoplasia, inflammation, etc may also contribute. No therapy is typically warranted for cats with ectopy with the exception of sustained tachyarrhythmias. The presenting episode of ataxia could potentially be explained by a tachyarrhythmia; that being said, we do not have enough information to determine cause and effect (ie the premature beats may simply be due to stress or secondary to the primary issue at play here). Going forward, recommend full systemic evaluation/BP as the next step given the rare nature of true arrhythmic ataxia in cats. If no underlying issues are uncovered and the episodes recur, reevaluating an extended ECG tracing is ideally recommended.

Monitor for any signs of progressive arrhythmias, including significant lethargy or collapse/syncope.

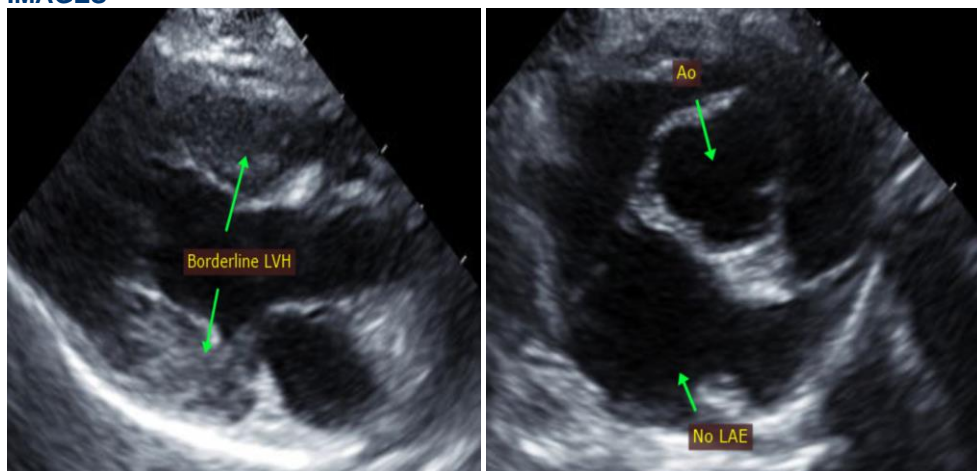
Anesthetic risk is considered mild. With this degree of remodeling and diastolic stiffening, there is an elevated risk for fluid overload in this patient and judicious IV fluid use is recommended. Heart rate stimulating drugs such as atropine, glycopyrrolate or ketamine should be avoided unless medically necessary.

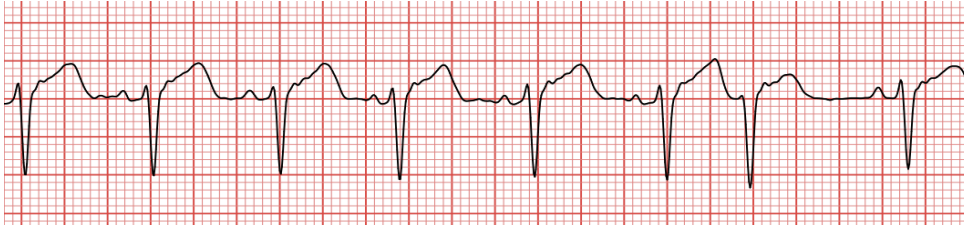
PLAN

Baseline BP is recommended. No obvious indication for Plavix from a cardiac standpoint; however, other possibilities should be considered. Full systemic evaluation. If the episodes recur undiagnosed, consider further arrhythmic evaluation as discussed.

Recommend recheck echocardiogram in 6-12 months to assess for progression, sooner if a murmur or gallop rhythm develops in the interim.

IMAGES





Premature beat

The information and recommendations provided are based on the images presented by the referring veterinarian. No evaluation can be communicated regarding pathology that was not visible in the image/video clips provided.

Thank you for this referral. This report was generated using transcription software, and minor dictation errors may be present. If the clinical or image interpretation does not parallel your findings or if I can be of any further assistance, please contact me.

Maggie Machen Lamy, DVM
Diplomate of the American College of Veterinary Internal Medicine (Cardiology)
info@sonopath.com